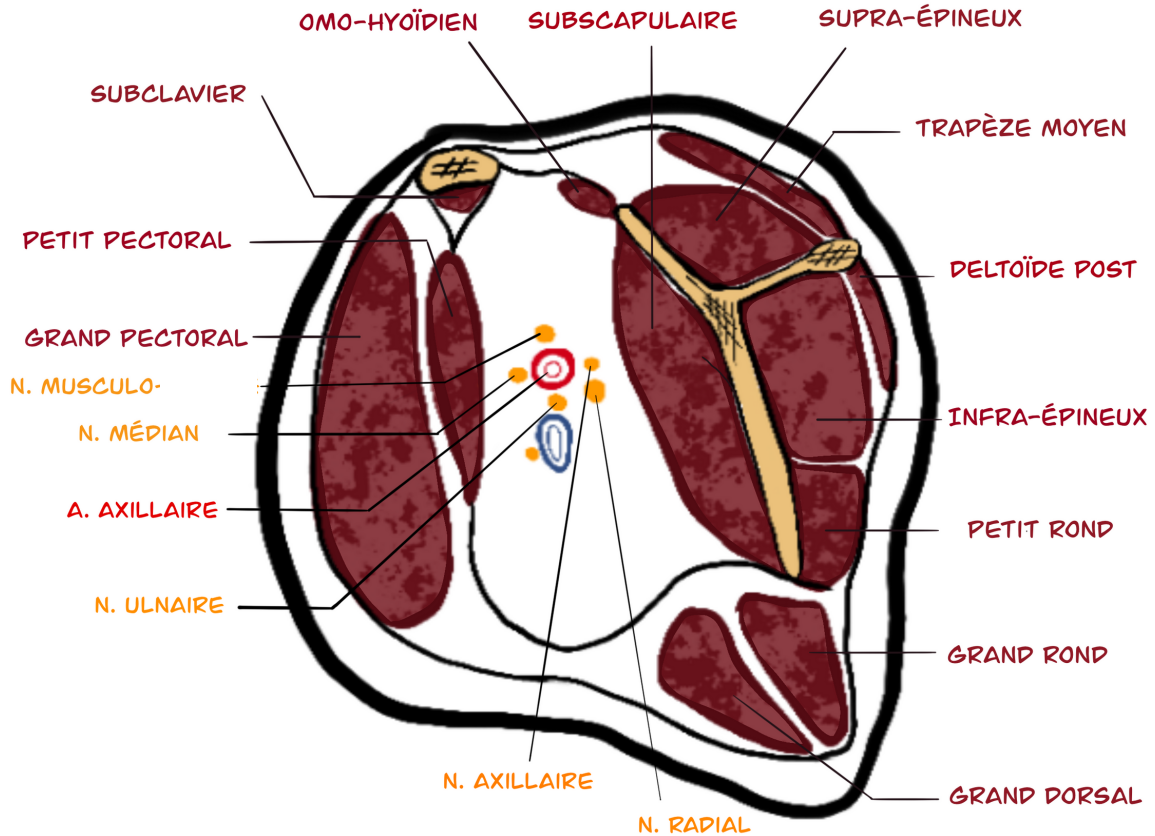
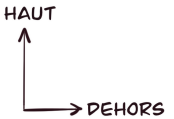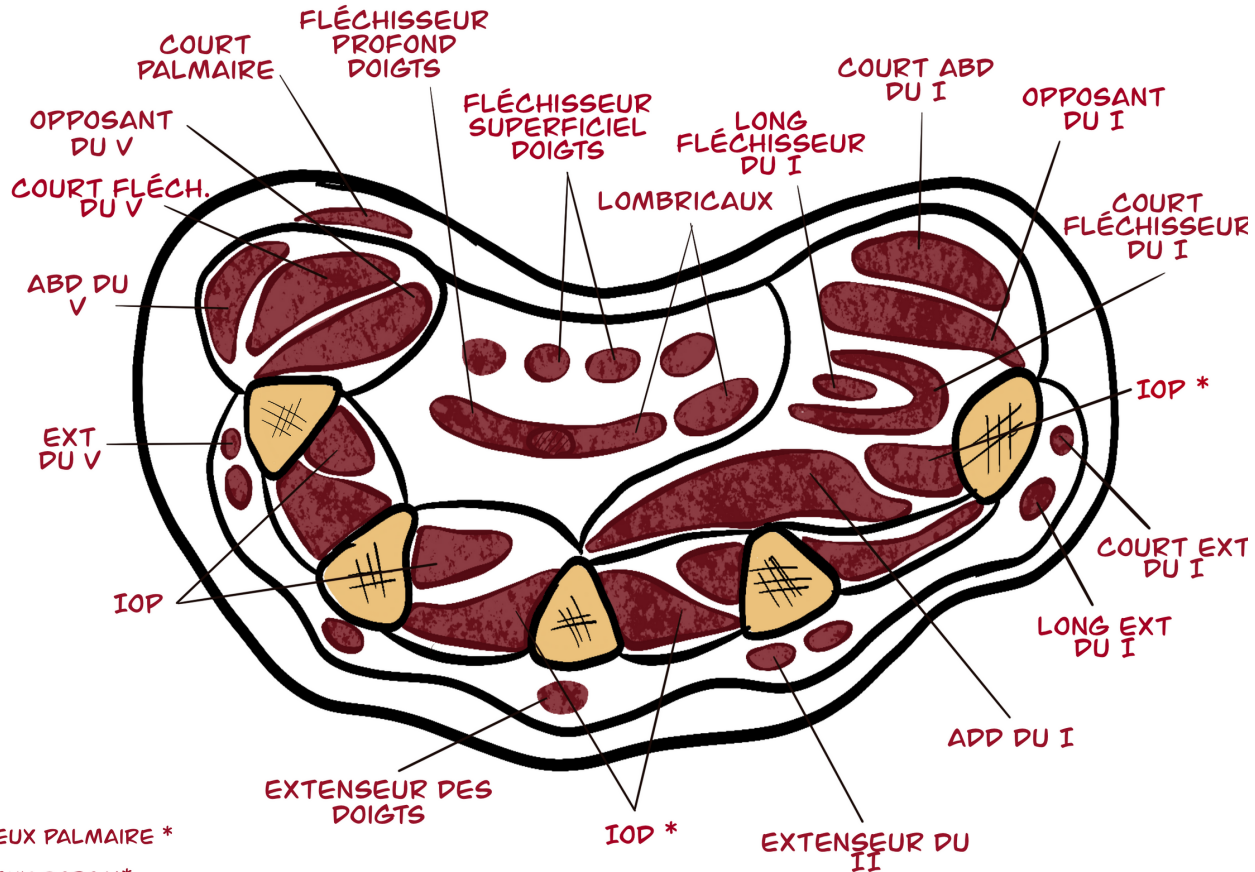
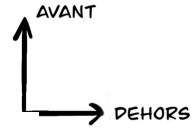


Coupe sagittale de l'épaule





Coupe transversale des métacarpiens



IOP INTEROSSEUX PALMAIRE *

IOD INTEROSSEUX DORSAL*

